

Transplantation of a bone block graft and insertion of a dental implant in a single surgical procedure

Vertical Augmentation with Bone Rings

Bernhard Giesenhausen, DMD, Melsungen, Germany

The technique presented here shows that exactly fitting annular bone grafts permit the three-dimensional vertical augmentation of bone defects and the insertion of dental implants in a single surgical procedure. Both the preparation of the recipient site and the harvesting of the bone graft are effected using trephine cutters. To this end, the implant bed within the transplant is removed before the transplant itself is harvested from the donor site, affording rigid fixation of the transplant with the aid of the implant itself.

Introduction

The two-stage method of surgical intervention has generally been employed in dental implantology in the case of three-dimensional bone defects augmented with autologous bone blocks. In order to prevent bone volume from getting lost during the healing phase of transplants, it is imperative for them to be fixed rigidly in place and to exhibit an excellent fit. Any remaining spaces can be filled with spongy bone fillings (obtained from the donor site) or bone replacement material. Covering the augmented area with a barrier membrane affords extra protection against resorptive processes. Since bone transplants tend to lose volume in the initial stage due to a process called adaptive atrophy, surgeons have found it helpful to augment the contours of the bone graft with slow-resorption bone replacement material to counteract the volume loss.

Method

The method presented here aims to combine the transplantation of a bone block graft and the insertion of a dental implant into a single surgical procedure. Several requirements must be met to achieve full treatment success:

1. There must be enough residual bone to provide primary stability for a dental implant.
2. The recipient site must provide as many vital cells as possible in close contact with the spongy aspect of the bone transplant.

3. The bone transplant must be rigid and completely immobile.
4. The implant must be correctly positioned for a successful prosthodontic rehabilitation.
5. The wound closure must be definitive, without any tension on the tissue.

Case Report

An 18-year-old man had suffered a sports accident that resulted in the fracture of the root of endodontically pre-treated (apical resection) tooth 12 and a luxation of tooth 11. Neither tooth was salvageable. We decided to remove the root fragments, followed by immediate bone augmentation and insertion of a dental implant.

Following extraction, a three-dimensional bony defect remained in the region of tooth 12, with bone fenestration in the region of tooth 11. The diameter of the graft required was defined by a trephine cutter 6 mm in diameter (Fig. 1 and 2). For all augmentation procedures, the bone level of the adjacent teeth is to be considered as the maximum bone level after bone augmentation.

Once the bone in the chin region had been exposed, a slight touch with a rotating trephine cutter defined the donor site of the bone transplant, with the cutter being one size larger than defined at the augmentation or recipient site (Fig. 3). This procedure is recommended because the size of the graft is defined by the internal diameter of the trephine cutter, while the external

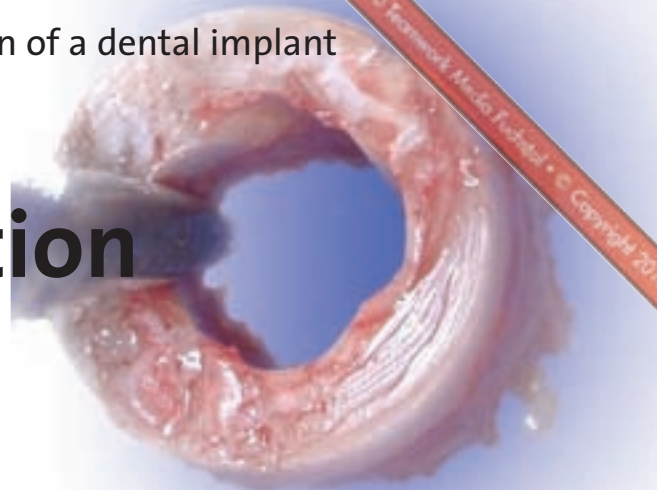


Fig. 1 and 2
The diameter of the graft required was defined by a trephine cutter 6 mm in diameter.

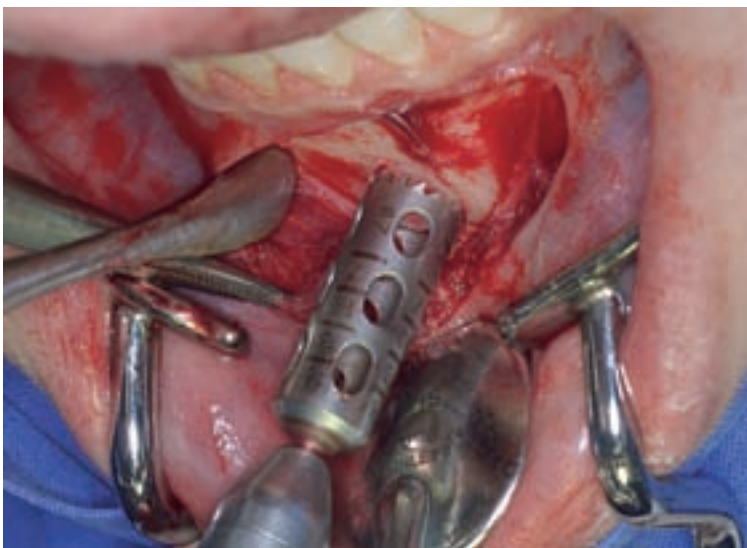
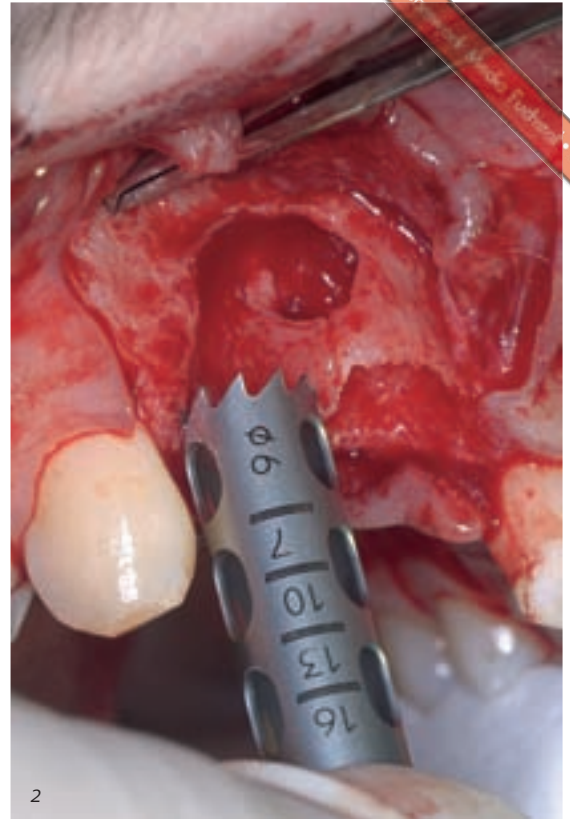
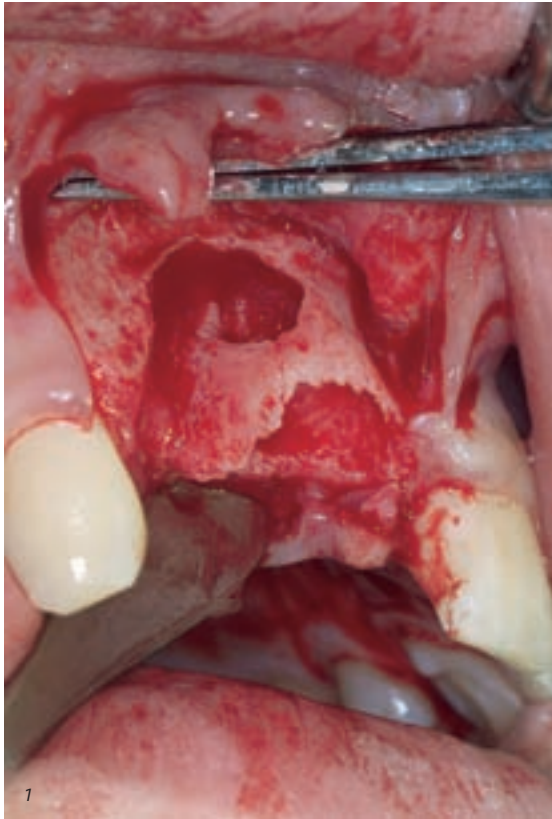

Fig. 3 The cutter used on the donor site was one size larger than the one defined at the augmentation or recipient site.

diameter of the trephine cutter determines the size of the preparation at the recipient site. Using two cutters of different diameters facilitates a snug fit of the transplant within the prepared bone. With the bone graft to be harvested still anchored in the bone, its centre was marked with a round bur (Fig. 4). The implant bed was prepared following the usual protocol, using a pilot drill, depth drills and – for the Ankylos implant system (Friadent) used and depicted here – also reamers and bone taps. It is very important to penetrate substantially the spongy bone of the donor region.

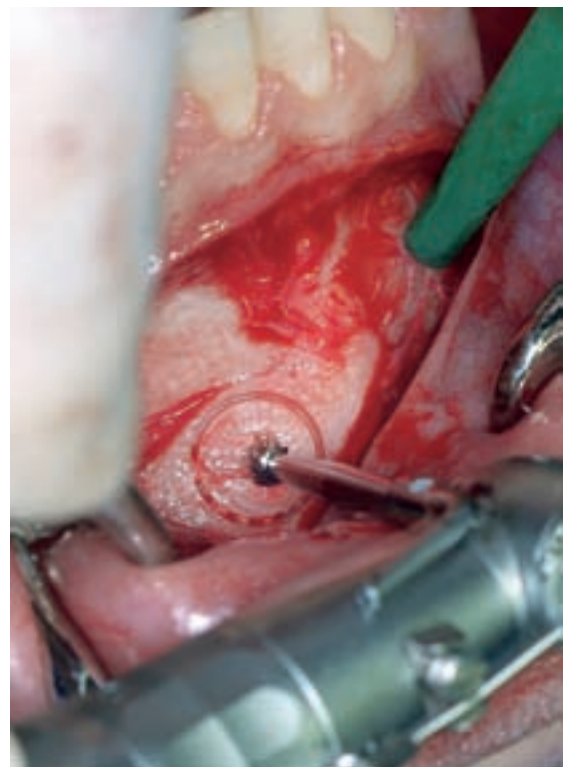


Fig. 4 The bone graft to be harvested was marked in its centre with a round bur.

In order to facilitate the removal of the bone ring, the bone transplant was prepared to its definitive depth using the trephine cutter. This must never be performed before the preparation of the implant bed has been completed, as the ring may otherwise loosen before the implant bed has been prepared properly – if

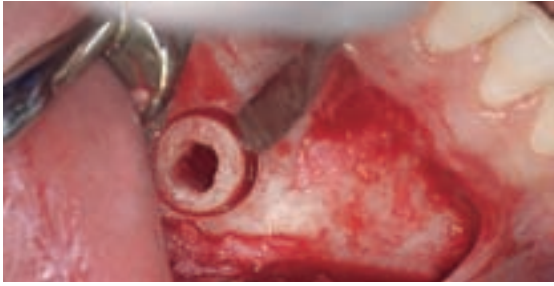


Fig. 5 The annular bone graft was easily removed using a bone rasp or a chisel.

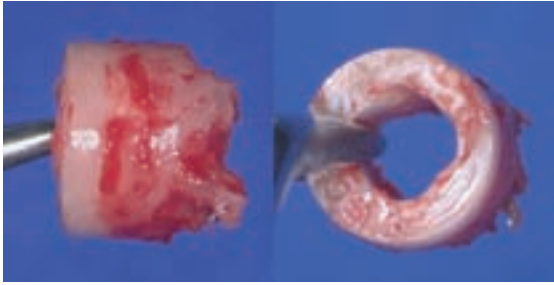


Fig. 6 The annular bone graft was put in place with its spongy aspect facing the depth of the donor site, while its cortical aspect encompassed the neck of the implant.

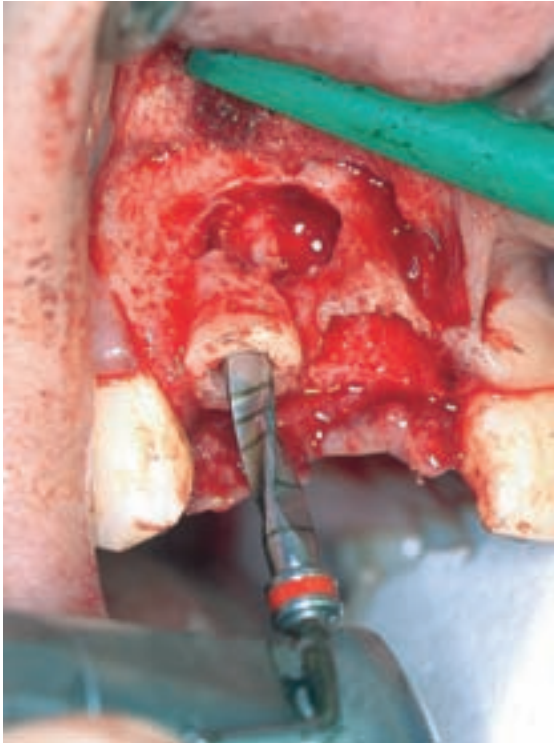


Fig. 8 The implant bed was prepared through the bone graft following the usual protocol.

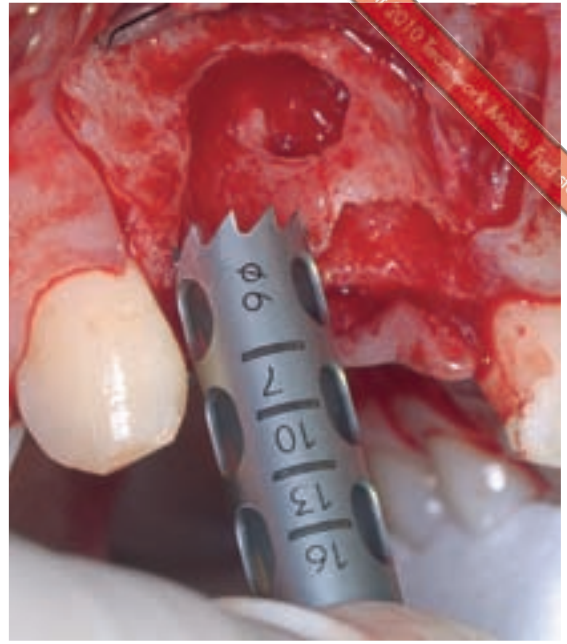


Fig. 7 The recipient site was prepared using the same trephine cutter.

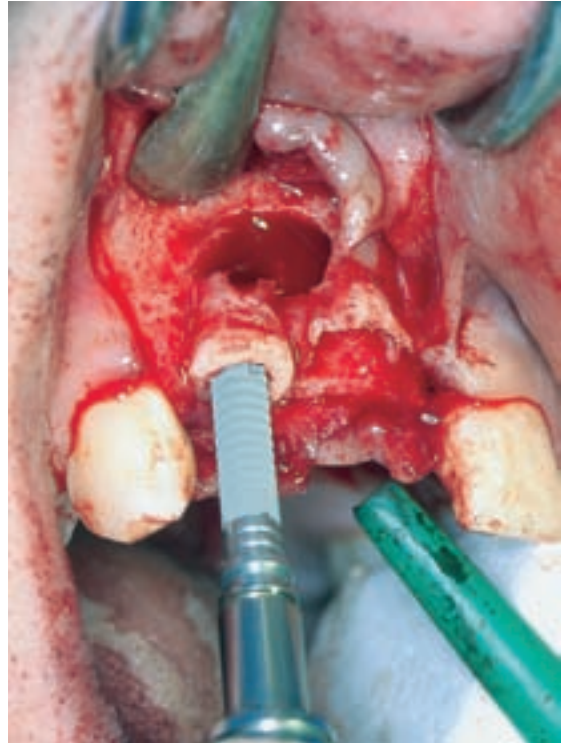
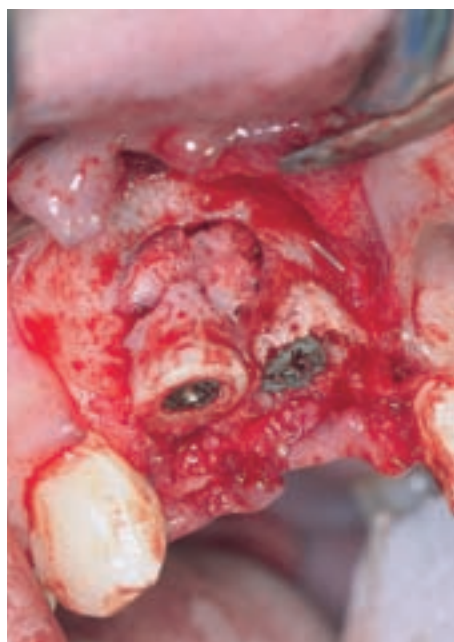

Fig. 9 Concentric markings on the insertion aid (adapter) assisted in proper subcrestal implant placement.

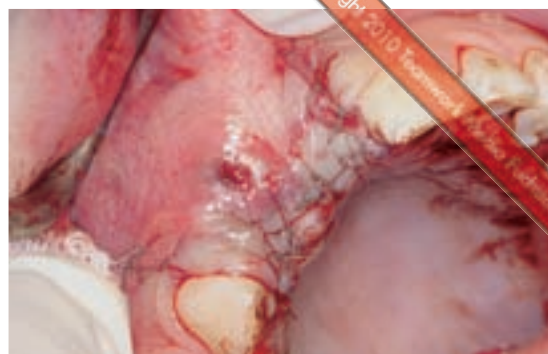the cortical bone layer is very thin – making subsequent steps very difficult. It is also advisable to increase the implant bed diameter in the area of the bone graft, as the annular graft may fracture if the cortical bone layer is very thin as the graft is subsequently fixed in place at the donor site by the implant. Also, insertion of the implant in its definitive position can be rendered difficult by a dense layer of cortical bone.

The annular bone graft was easily removed using a bone rasp or a chisel (Fig. 5). To cover the fenestration area in the region of tooth 11, another bone segment was harvested, and the defect was filled with collagen fleece and sutured closed. The annular bone graft (Fig. 6) was put in place with its spongy aspect facing the depth of the donor site, while its cortical aspect encompassed the neck of the implant. To this end, the recipient site was prepared using the same trephine cutter (Fig. 7). Protruding bone

segments were removed with a bone chisel and collected for later augmentative modelling. Once the bone graft had been inserted, the local bone is marked with a bur passing through the inside of the graft in order to indicate the position of the dental implant. The implant bed was prepared through the bone graft following the usual protocol (Fig. 8). The implant was also inserted through the bone graft, obtaining primary stability from the local bone and using its crestal threaded portion to keep the bone graft in place. Concentric markings on the insertion aid (adapter) assisted in proper subcrestal implant placement (Fig. 9). The second dental implant, in the region of tooth 11, was inserted, and the remaining apical defect on implant 12 was filled with parts of the second bone segment harvested from the chin. The sharp edges of the bone graft were smoothed, and the bone graft in its entirety was contoured to match the anatomical situation at the recipient site.



*Fig. 10
Spongy bone obtained from the donor region was used for additional augmentative modelling.*



*Fig. 11
Before being covered, the bone graft area was covered with granular bone replacement material.*

CONTACT ADDRESS:

Bernhard Giesenhausen, D.M.D.
Medical Director, Pro-Implant Institute
Institute for Dental Implantology and
Aesthetic and International Training Centre

Obere Mauergasse 2 / Am Bitzen 6
34212 Melsungen
Germany
Phone: +49 5661 923270
Fax: +49 5661 923271
E-mail: info@pro-implantnet

Spongy bone obtained from the donor region was used for additional augmentative modelling (Fig. 10). The entire site was covered with a membrane (Biogide, Geistlich). To this end, the membrane was first immobilized apically using membrane pins (Friadent). Before being covered, the bone graft area was covered with granular bone replacement material (BioOss, Geistlich) to

protect the graft from resorption during the healing phase (Fig. 11).

Thanks to the special thread geometry of the Ankylos implants with its excellent primary stability, a depth of two to three threads in the local bone is sufficient for this technique. Bone augmentation for maxillary sinus floor elevation can be performed in the same manner. ■